



PATIENT

Kiki Sydow

SPECIES

Feline

BREED

DMH

SEX

FS

AGE

10yr

WEIGHT

3.5kg

INTERPRETED BY

R. McKenzie Daniel,
DVM, DABVP
(Canine and Feline)

IMAGING PERFORMED BY

Kristi Whitten

HOSPITAL NAME

North Fork Veterinary
Clinic

REFERRING VET

Katherine Jordan

INVOICE 23316

DATE 12/22/2025

PRESENTING CLINICAL SIGNS

Medical History Narrative Summary Kiki, a 10-year-old spayed female Domestic Longhair, has a recent history of vomiting, lethargy, and decreased appetite Beginning on 12/04/25, Kiki presented for a week of retching and vomiting. Bloodwork at that time showed an elevated HCT (53.1%) and HGB (17.0 g/dL), with a low lymphocyte count (0.66 K/uL). A recheck on 12/18/25 for continued lethargy and vomiting prompted the owner declined further diagnostics at that time. Kiki was treated with SQ fluids, Dexamethasone, and Cyanocobalamine. As of 12/22/25, vomiting was an ongoing concern, and the patient received an injection of Cerenia.

Abnormal PE/Chem/CBC/UA Results: PE: mild dehydration. Normal TPR. Tender in mid abdomen. 12/04/25, elevated HCT (53.1%) and HGB (17.0 g/dL), with a low lymphocyte count (0.66 K/uL).

ULTRASONOGRAPHIC EXAMINATION OF THE ABDOMEN

Urinary System

The urinary bladder, trigone, cystourethral junction, and visible pelvic urethra exhibited normal thickness and tone. Anechoic urine was present in the lumen with mild non-dependent particulate sediment. The ureteral papillae were normal. The ureters were not visible which is normal. No evidence of inflammatory or neoplastic changes was noted.

Normal size and margination were present in the kidneys. A normal 1:3 cortex / medulla ratio was maintained. The medulla and cortices were uniform in texture with some increased echogenicity and mild loss of corticomedullary symmetry and definition expected for the age of the patient. No evidence of pelvic dilation was present. The left kidney measured 4.1 cm in length. The right kidney measured 4.3 cm in length.

The area of the aortic trifurcation was free of pathology.

Adrenal Glands

The left and right adrenal glands were not definitively visualized.

Spleen

The spleen was not definitively visualized.

Liver/Gallbladder

The liver was subjectively normal in size, structure, and contour. The liver parenchyma was uniform and hypoechoic to the spleen with a mild coarse echotexture. Normal vascular volume. The hepatic and portal vasculature were normal in appearance without signs of congestion. The gallbladder was non-distended in size with thin walls and primarily anechoic luminal content. The cystic and common bile ducts were normal.

Gastrointestinal

The stomach presented intact wall layering with a normal wall layer ratio. The lumen of the stomach was empty with no signs of ileus, obstruction or foreign material. The pylorus wall measured 0.25 cm in width.

The small intestine presented intact wall layering with 1:3 muscularis/mucosa ratio. Mild segmental jejunal corrugation was present. The lumen of the small intestine was empty with no signs of



PATIENT

Kiki Sydow

mechanical/metabolic ileus, obstruction or foreign material. The small intestinal wall measured 0.21 – 0.22 cm in width.

Normal visible colon wall layers were present with apparent formed feces in lumen.

SPECIES

Feline

Pancreas

The area of the pancreas was sonographically normal.

Free Abdomen

BREED

DMH

No omental masses or peritoneal effusion was present.

SEX

FS

Intermittent minor prominent to enlarged colic lymph nodes were present. The lymph nodes were essentially isoechoic to adjacent omentum without evidence of peripheral inflammation and maintaining a normal width: length ratio (<0.5).

ULTRASONOGRAPHIC FINDINGS

Primary

AGE

10yr

- Sonographically normal gastrointestinal tract with minor segmental jejunal corrugation
- Normal area of pancreas
- Age-related renal changes.
- Urine sediment

WEIGHT

3.5kg

INTERPRETATION OF THE FINDINGS & FURTHER RECOMMENDATIONS

No evidence of overt gastrointestinal mural pathology, i.e. masses, definitive IBD intestinal criteria or mechanical gastrointestinal obstruction. At times, underlying gastrointestinal disease or mild pancreatitis in cats may present sonographically normal. A GI panel to include PLI/TLI/Cobalamin/Folate may be considered to assess for non-structural intestinal disease or mild pancreatitis. Potential suppression of intestinal pathology owing to recent steroid therapy may be possible. Three view chest radiographs are recommended to assess for or rule out thoracic pathology as a contributing factor.

INTERPRETED BY

R. McKenzie Daniel,
DVM, DABVP
(Canine and Feline)

Gastrointestinal support, which may include dietary trial and gastric protectants with clinical monitoring is recommended. Sonographic reassessment is indicated if continued or progressive gastrointestinal signs or weight loss.

IMAGING PERFORMED BY

Kristi Whitten

HOSPITAL NAME

North Fork Veterinary
Clinic

REFERRING VET

Katherine Jordan

INVOICE

23316

DATE

12/22/2025



PATIENT

Kiki Sydow

SPECIES

Feline

BREED

DMH

SEX

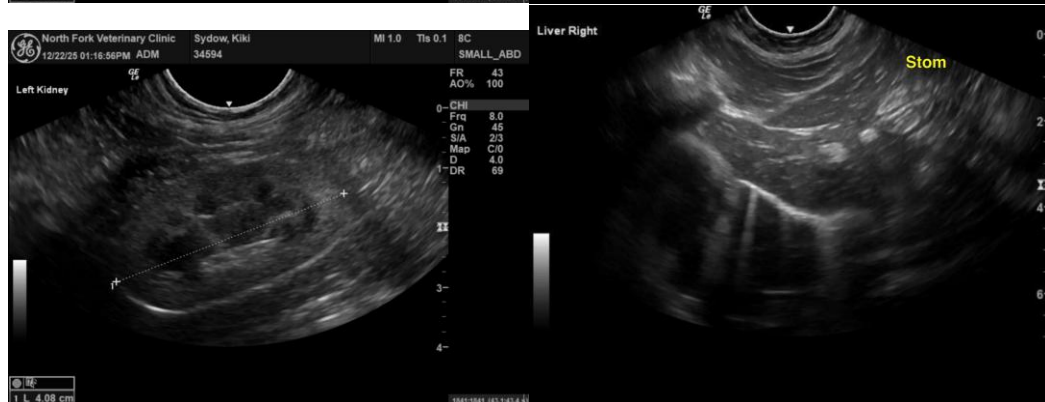
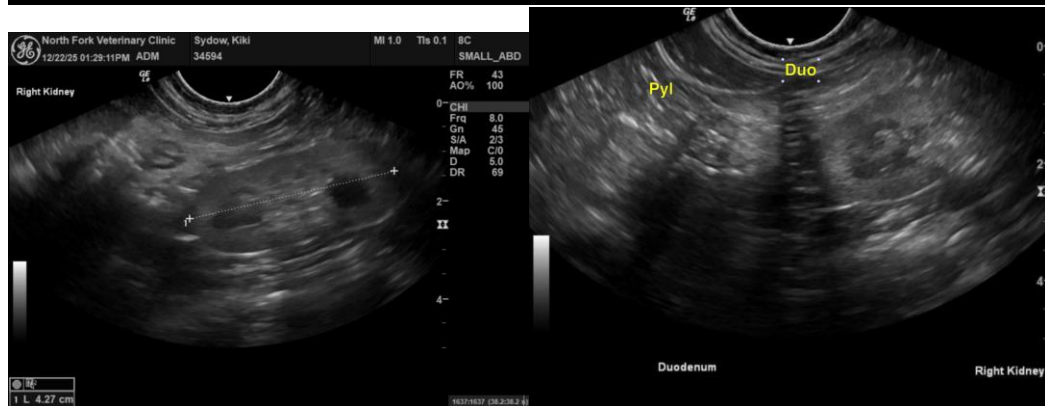
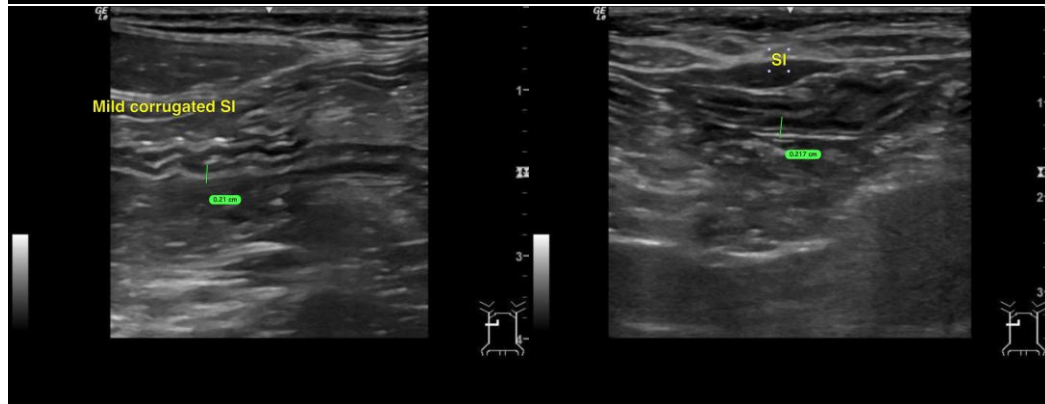
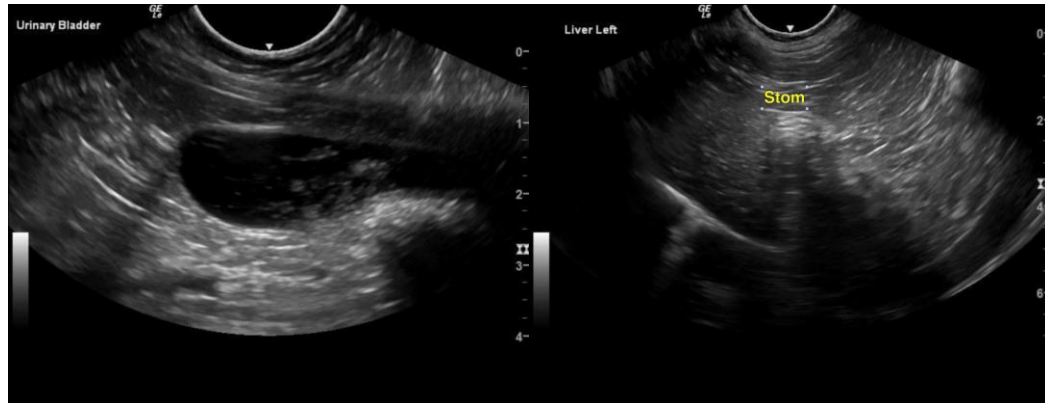
FS

AGE

10yr

WEIGHT

3.5kg



INTERPRETED BY

R. McKenzie Daniel,
DVM, DABVP
(Canine and Feline)

IMAGING PERFORMED BY

Kristi Whitten

HOSPITAL NAME

North Fork Veterinary
Clinic

REFERRING VET

Katherine Jordan

INVOICE

23316

DATE

12/22/2025



PATIENT

Kiki Sydow

SPECIES

Feline

BREED

DMH

SEX

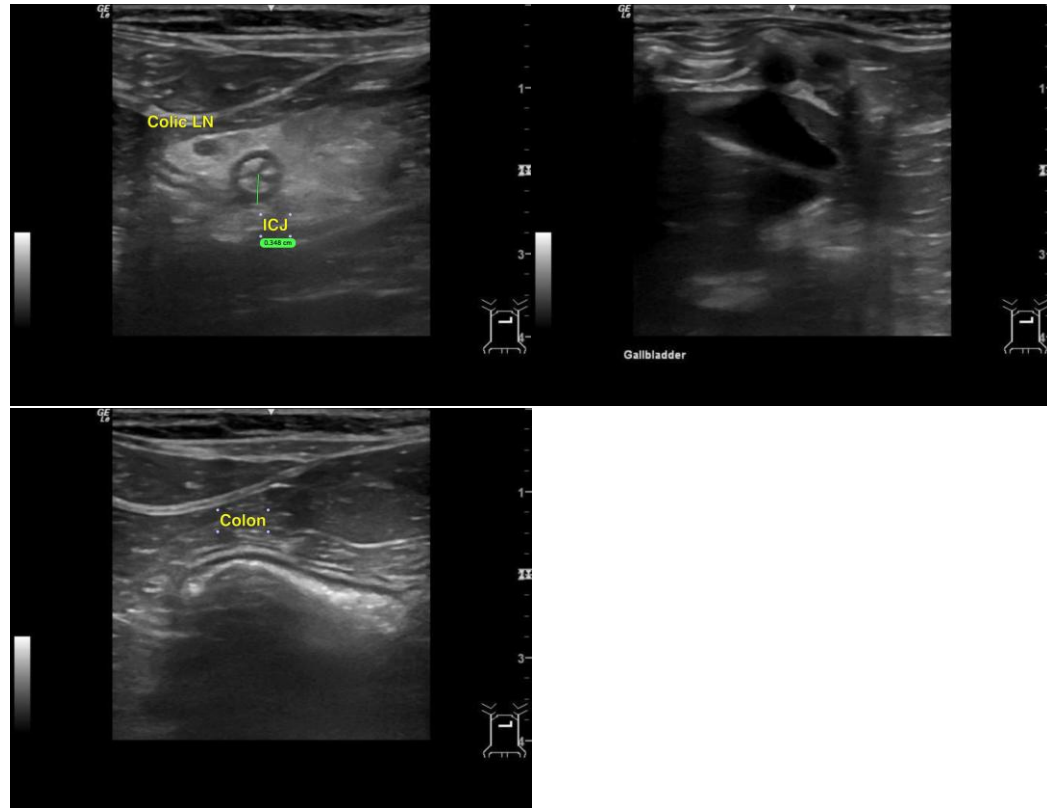
FS

AGE

10yr

WEIGHT

3.5kg



INTERPRETED BY

R. McKenzie Daniel,
DVM, DABVP
(Canine and Feline)

IMAGING PERFORMED BY

Kristi Whitten

HOSPITAL NAME

North Fork Veterinary
Clinic

REFERRING VET

Katherine Jordan

INVOICE

23316

DATE

12/22/2025

The information and recommendations provided are based on the images presented by the referring veterinarian/sonographer. No evaluation can be communicated regarding pathology that was not visible in the image/video clips provided.

Thank you for this referral. If the clinical or image interpretation does not parallel your findings or if I can be of any further assistance, please contact me.

R. McKenzie Daniel, DVM, DABVP (Canine/Feline Practice)
info@sonopath.com